15 December 2016

TO WHOM IT MAY CONCERN

MEDICAL REPORT

NAME OF PATIENT	:	**MIRAH ALI MOHAMED**
REGISTRATION NO.	:	**565 31 26**
DATE OF BIRTH	:	**22 AUGUST 1999**
NATIONALITY	:	**UAE**
GENDER	:	**FEMALE**

Diagnosis

- Congenital cerebellar hypoplasia
- Hereditary spastic paraplegia
- Familial spasticity
- Multiple gene mutations on exome sequencing; parents counselled by the genetic team.

Reference:

- Medical report on 28 February 2016
- Medical reports issued from Latifa Hospital on 21 October 2000, July 2002, June 2003 and October 2007, 19 January 201 and 20 July 2014.
- Medical reports from Germany in February 2005, 20 April 2007, 2008 and March 2010. Medical reports from India in 2003.
- Medical reports from a Visiting Pediatric Rehabilitation Consultant on 06 December 2004, 15 November 2005, 12 December 2006, 23 May 2007 and 20 June 2009.
- Medical Report issued from Dr. Carlos, a visiting Pediatric Neurologist, Latifa Hospital on 22 November 2010.

Mirah is 16 years 4 months old girl, a known case of cerebellar hypoplasia and motor developmental delay with diplegic distribution spasticity, and hereditary spastic paraplegia. She had regular follow up in Pediatric Neurology Clinic. Mirah's brothers Mayed and Mansoor gave similar clinical history of increasing spasticity in the lower limbs from the age of six months. They have been identified as having possible hereditary spastic paraplegia.

Mirah was seen several times by visiting pediatric rehabilitation medicine and had several sessions of intramuscular botox and 5% phenol injections at lower limbs muscles as well as continuous intensive physiotherapy and muscles stretching. Foot and ankle braces for bilateral talipes valgus deformity. She was evaluated in Germany in February 2007 and in 2013 and had left salter osteotomy and right salter osteotomy in February

2008 and she had also lengthening of tendon of Achilles; there were no post-operative complications and she showed good progress and was able to walk better.

Mirah has, in addition, hearing defect and visual weakness. She was seen by audiologist in Germany; hearing tests showed the left auditory nerve damage which is not suitable for hearing aids and also was evaluated by Ophthalmologist and reported bilateral strabismus and had operation for bilateral squint correction in 2005 and currently uses glasses.

Mirah and her brothers Mayed and Mansoor were seen by Dr. Carlos Visiting Consultant Pediatric Neurology in Latifa Hospital on 22 November 2010 who reported that the three siblings have similar medical conditions: increase in leg tones and spasticity, delayed in walking, initial tiptoeing with all the three siblings being fairly normal in their school performance.
Mirah and Mayed have experienced some difficulty with hand writing and fine motor skills. The impression was that the three siblings have hereditary spastic paraplegia and further investigations were recommended in addition to genetic counseling.

Investigation:

- Molecular analyses for hereditary spastic paraplegia type 4 (SPG4), Hereditary spastic paraparesis 31 (SPG 31). Conclusion: The results cannot confirm the diagnoses of hereditary spastic paraplegia due to these specific mutations.
- DNA extraction report:
- Long Chain Fatty Acids: Test result unit's essentially normal levels of VLCFAs with normal ratios. No indication of an inherited paroxysmal disorder
- Amino acid / Acylcarnitine screen normal.
- Urine organic acid screening normal.
- Brain MRI showed small sized posterior fossa and cerebellum, moderate symmetrical widening of lateral ventricles, multiple small focal areas of high signals scattered into deep periventricular white matter of both cerebral hemispheres, no mid line shift, well developed corpus callosum and no neuronal migrational abnormality.
- Whole exome sequencing (28/02/2016): A 4 mutation has been detected:
    1. Homozygous mutation, p.Gln1527*, c.4579C>T detected in LAMA 1 gene
       Mother and father heterozygous.
    2. Homozygous mutation, p.Val221Ala; c.662T>C; exon 6 detected in C5orf42 gene.
       Mother and father are heterozygous.
    3. Homozygous mutation, p/His 231 Arg; c.692A>G>C; exon 7 detected in C5orf42 gene.
       Mother and father are heterozygous.

4. Two heterozygous mutation detected in PMM2 gene, rs201556985, (p.Asp 30Glu; c>90C>G in exon 2) and rs368512236,c, 256-44A> in exon 3). Mother and father are heterozygous.

Mirah was last seen in the neurology clinic in August 2016. She was attending a mainstream school and was doing quite well although she did have problems with her handwriting. She had good self-help skills. She has slow speech but improving. She walked with a limp. Her gait improved after osteotomy done in Germany recently. On examination, spastic diplegia was unchanged with tightness of hamstrings and gastrocnemii. The left lower limb appear shorter, possibly indicating persisting femoral rotation. The parents were advised about the need to continue intensive physiotherapy and rehabilitation programs. She was on vitamin D3 supplementation which was increased to 1200 IU OD. Orthopedic management needs to be reviewed. Her exome has shown several gene mutations. I understand the genetic team has counselled the parents regarding the significance of these mutations. She will be transferred to Neurology unit; Rashid Hospital in view of her age.

This medical report is issued at the request of parents.

DR. GURURAJ AITHALA
MD, DCH, MMED, MRCP (UK), FRCPCH,
Consultant Paediatric Neurologist
Latifa Hospital

هيئة الصحة بدبي
Dubai Health Authority
مستشفى لطيفة
Latifa Hospital

EMBASSY OF THE
UNITED ARAB EMIRATES
MILITARY ATTACHE OFFICE
BERLIN

سـفـارة
الإمارات العربية المتحدة
مكتب الملحقية العسكرية
برلين

01.10.2015
649/14/g.a.

MEDICAL REPORT
(Translation)

VOLMARSTEIN CLINICS WETTER
Orthopedic Clinic -Department of Pediatric and Neuro-Orthopedics
Dr. Benedikt Leidinger

Al Qassab, Meera, dob 22.08.1999
Consultation on 29.09.2015 (OPD)

Diagnosis:
Paraspasticity
C.a. sub-condylar osteotomy both femurs
Stiff-knee gait left side
Extension deficit left side

Procedure:
Further treatment after nine months, then perhaps extension osteotomy with patella distalization left knee-joint; metal removal right side

Meera shows a good rehabilitation result. The pains in her knee-joint have receded entirely. She has made good progress regarding her mobilization. She is already able to conduct an alternating gait pattern bearing weight on either side. On the left side the gait pattern is limited through a so-called stiff-knee-gait. Here, there is an extension deficit of -15° with hard stop. A Botulinum toxin therapy into the ischio-crural muscles was carried through which finally led to a functional improvement. On the right side she wears an ankle-embracing orthosis, on the left side an orthosis reaching up to the calf for stabilization of the feet and when walking.

After nine months Meera should continue her treatment; until then continuation of physiotherapeutic exercises with physiotherapy on neurophysiological basis.

Signature

TRANSLATION AUTHORIZED AND CONTROLLED BY THE
UAE EMBASSY - BERLIN
MILITARY ATTACHE - HEALTH OFFICE - BONN
ترجمة معتمدة من
سفارة الإمارات العربية المتحدة - برلين
الملحقية العسكرية - المكتب الصحي - بون
IN CASE OF DOUBT AS TO THE PROPER INTERPRETATION
OF THE REPORT THE GERMAN TEXT SHALL PREVAIL

EMBASSY OF THE
UNITED ARAB EMIRATES
MILITARY ATTACHE OFFICE
BERLIN

سفارة
الإمارات العربية المتحدة
مكتب الملحقية العسكرية
برلين

04.10.2015
649/14/g.a.

MEDICAL REPORT
(Translation)

HELIOS CLINIC HOLTHAUSEN
Center for Neurosurgical and Neurological Rehabilitation
Dr. Axel Petershofer

Al Qassab, Meera Ali Mohammad, dob 22.08.1999
In-patient from 12.02.2015 until 04.10.2015

Diagnoses:
Hereditary spastic paraparesis

Internal rotation gait with knee extension deficit both sides
C.a. derotating valgizating osteotomy right distal femur and derotationg varizating osteotomy with axis correction left and right distal femur. osteosynthesis with Pleo-plate both sides on 27.03.2015
C.a. BTX-injection on 01.09.2015
Contractures of various joints on both sides

Therapeutic aims and therapy:
Part of the therapy at our clinic were the strengthening of the leg muscles, the improvement of the gait pattern, the extension of the walking distance and the promotion of the fine motor and coordinative capabilities.

Meera was integrated into a multi-disciplinary therapy concept consisting of medical treatment and therapeutic care, physiotherapy, occupational therapy, group therapy and speech therapy.
In addition to this repetitive walking exercises in the Lokomat (gait robot). Meera attended classes at the hospital school.

Rehabilitation course:
Medical course:
Due to the apparent signs of an iron deficiency a therapy was started with Ferro sanol capsules 100 mg 1 x 1 daily. In the meantime the HB-level has risen well, and the ferritin level has also turned normal, so that this medication could be stopped again.
On the 01.09.2015 Botox injection, which was quite beneficial for Meera.

Physiotherapy:
Within the framework of the physiotherapeutic rehabilitation Meera has continuously made little progress.
Meera has obviously gained more confidence in walking as regards her left side, though she is still at risk to fall, especially backwards.
Meera participated in the Galileo- and Lokomat therapies.
In addition to this the sports therapy could be intensified. Meera regularly received tapes (Kinesiotape) to reduce the tonus at the lower extremities.
The girl also received a program for exercises serving for the regular stretching without assistance.
We prescribed:
1 movement trainer with accessories
1 pair of forearm crutches

Another physiotherapeutic measure is recommended in order to preserve the ROM and to further improve the gait pattern up to a stage, where she will be able to walk freely, confidently and without any medical appliances.

Occupational therapy:
Within the framework of the occupational therapeutic rehabilitation Meera achieved individual progress in the fields of mobility, emotional competences and sensorimotor capabilities.
By the time of being discharged a 30-minute walk is possible with a short pause.
Owing to special handicraft techniques she could enhance her eye-hand-coordination.
In addition to this she could improve her cognitive capabilities.
He is discharged into his home environment.

Status at the time of the discharge:
Activities concerning self-care:
Meera is now able to get dressed and undressed without help. Taking showers including washing her hair is also possible without assistance. Bilateral handling of cutlery is possible. She can go to toilet without help.

Activities relating to mobility:
She walks with two forearm crutches and an escort. She is independent with a retro-walker. Transfers and changes of position are performed without help. She is able to climb stairs with one forearm crutch and holding the handrail.

Activities relation to communication:
Meera speaks English, her mother tongue is Arabic.

Activities concerning the life at home:
She is able to help, e.g. to lay the table or bring something to the table.

Participation / profession / leisure time:
She attends a regular school. the teachers there have consideration for her learning disorder; in her leisure time she loves meeting with her friends.

Sensorimotor functions:
The ROM of the upper extremities is free in the end-degree. The finger-to-finger, eye-to-hand and hand-to-hand coordination is restricted. In addition to this there is a heterophoria which has a negative effect on the dexterity.

Cognitive and emotional functions:
The patient shows deficits in the fields of planning an action and visual-spatial perception. The working speed is reduced.

Further out-patient occupational treatment of the sensorimotor and cognitive functions is recommended, in order secure and to further promote the results achieved so far.

Speech therapy:
There is a mild dysarthria. By strengthening the muscles of the tongue speaking has improved. Together with the girl an exercise book was set up enabling her to continue making exercises on her own beyond the setting of the therapy.

Motivation and cooperation of the patient:
Meera was always motivated and cooperative in the therapies.

Clinical and social medical epicrisis:
Rehabilitation results and final findings:
On discharge Meera was in a good general condition. No signs of an infection. The ROM of both knees has improved considerably. Passive extension of both knees up to 0°. During the active movement a deficit of 10° remained on the left side. The gait pattern is far less marked by the previous dorso-rotation and the insufficient extension of the knees. Also the bearing of weight on the left leg has become much better. Walking with crutches in the four-point-gait is possible without problems. Meera is able to climb stairs (upwards step by step, and downwards with assistance).

Barthel on admission: 60
Barthel on discharge: 60

Critical appraisal of the rehabilitation process and result:
The walking and the gait pattern could be improved considerably.

Prescribed medical appliances:
Lower-leg orthosis left side and ankle-embracing orthosis right side
1 pair of forearm crutches

1 movement trainer with accessories

Social-medical epicrisis:
Meera has been discharged to return to her home country.

Recommended further measures and after-care:
Further diagnostics:

- In view of the expected reduction of the effect of the botulinum toxin after about 2 months and the corresponding deterioration of the gait pattern, another BTX-therapy is indicated
- For further intensive improvement of the gait pattern, also with the help of the Lokomat-therapy, another in-patient rehabilitation is indicated after around 9 months

Further therapy:
Physiotherapy (to preserve the ROM of the legs and to further improve the gait pattern)
Occupational therapy (further treatment of the sensorimotor and cognitive functions)

Medication on discharge:
None

Signature

TRANSLATION AUTHORIZED AND CONTROLLED BY THE
UAE EMBASSY - BERLIN
MILITARY ATTACHE - HEALTH OFFICE - BONN
ترجمة معتمدة من
سفارة الإمارات العربية المتحدة - برلين
الملحقية العسكرية - المكتب الصحي - بون
IN CASE OF DOUBT AS TO THE CORRECT INTERPRETATION
OF THE REPORT THE GERMAN TEXT SHALL PREVAIL

Orthopädische Klinik
VOLMARSTEIN

Lothar-Gau-Straße 11
58300 Wetter

Evangelische Stiftung Volmarstein · 58292 Wetter

Orthopädische Klinik

Zentrum für Orthopädie und Unfallchirurgie

Allgemeine Orthopädie und Unfallchirurgie
Chefarzt Dr. Matthias Gansel

Kinderorthopädie und Neuroorthopädie
Chefarzt Dr. Benedikt Leidinger

Tumororthopädie und Revisionschirurgie
Chefarzt Prof. Dr. Carsten Gebert

Hand- und Plastische Chirurgie
Ltd. Arzt Kemal Esen

Wirbelsäulenchirurgie
Chefarzt Dr. Axel Scharfstädt

An die
Botschaft VAE
Hiroshimastr.

10 Berlin

Durchschrift an	unser Zeichen	Auskunft erteilt	Durchwahl	
	0000401394 /Sch	Sekretariat Frau Schäfer E-Mail: kinderortho@esv.de	02335 639 4561	Wetter (Ruhr), 03.04.2015

Entlassungsbericht

Patientin: Al Qassab, Meera geb.: 22.08.1999 Wohnort: 10785 Berlin, Hiroshima Str. 18

Wir berichten über den stationären Aufenthalt unserer gemeinsamen Patientin vom 26.03.2015 bis 03.04.2015:

Diagnose:
G80.0 Spastische tetraplegische Zerebralparese beidseits
Q65.0 Innenrotationsgang und Knie-Streckdefizit beidseits
M24.50 Gelenkkontraktur: Mehrere Lokalisationen beidseits

Therapie:
5-781.9h Derotierende valgisierende Osteotomie Femur distal rechts
5-781.9h derotierende varisierende Osteotomie mit Achsenkorrektur: Femur distal links
5-786.3 Osteosyntheseverfahren: Durch Pleo-Platte beidseits

Nicht operative Prozeduren:
8-563.0 Krankengymnastische Mobilisation Knie, Transfer in den Rollstuhl

Prozedere:
Stationäre Wiederaufnahme in 6 Wochen nach OP zur Mobilisation für ca. 1-2 Wochen, Stehen, Gehen. Danach Verlegung und Weiterbehandlung in die stationäre Rehabilitationsklinik für 4 Wochen Rehabilitation mit dem Ziel: Mobilisation, Verbesserung der Muskelkraft, Gangschulung, Muskeldehnung.
WV 6 Wochen postoperativ zur klinischen und radiologischen Kontrolle (mit GBA Röntgen). Fortführung der Thromboseprophylaxe bis zum Erreichen der präoperativen Vollbelastung

Betreff: Al Qassab, Meera geb.:22.08.1999, Aufenthalt vom: 26.03.2015

Vorgeschichte:
Meera stellte sich am 08.12.2014 zur Kontrolluntersuchung vor. Sie läuft frei, ist aber im starken Kauergang. Beide Knie werden im Kauergang gebeugt benutzt und dabei stark nach innen gedreht.

Die klinische Untersuchung zeigte eine Rotationsfähigkeit in den Hüftgelenken von IRO/ARO 30-0-30° rechts, 45-0-30° links. Die ischiokurale Muskulatur zeigt ein Streckdefizit von 15° beidseits, die OSG-Beweglichkeit in Dorsalextension beträgt 0°. Die Abspreizfähigkeit beider Hüftgelenke beträgt 30°. Beidseits Pes planovalgus. Die heute durchgeführte Röntgenkontrolle des Beckens zeigt eine zentrierte Hüftgelenkssituation, eine gute korrigierte neurogene Hüftdysplasie.
Wegen der starken funktionellen Beeinträchtigung durch den Kauergang empfahlen wir die Durchführung einer derotierenden extendierenden suprakondylären Femurosteotomie beidseits in einem simultanen Eingriff und vereinbarten mit der Familie einen Operationstermin.

Verlauf:
Am 27.03.2015 erfolgte der o.g. Eingriff nach entsprechender Vorbereitung und Aufklärung. Der intra- und postoperative Verlauf gestaltete sich komplikationslos. Es erfolgte die mehrdimensionale Korrekturosteotomie zur Derotation, Extension und Varus-Valgus-Korrektur. Die Drainage wurde am 1. postoperativen Tag entfernt werden. Es erfolgte täglich KG mit Mobilisation des Kniegelenkes und zur Remobilisation zum Transfer vom Bett in den Rollstuhl. Dies wurde zuletzt problemlos bewerkstelligt. Knieflexion zur Entlassung bds. 90 Grad passiv. Im Verlauf zeigte sich eine reguläre reizlose Wundheilung bei intakter DMS. Die postoperativ durchgeführte Röntgenkontrolle zeigte eine gute Stellung, Korrektur und unverändert korrekt einliegendes Osteosynthesematerial.

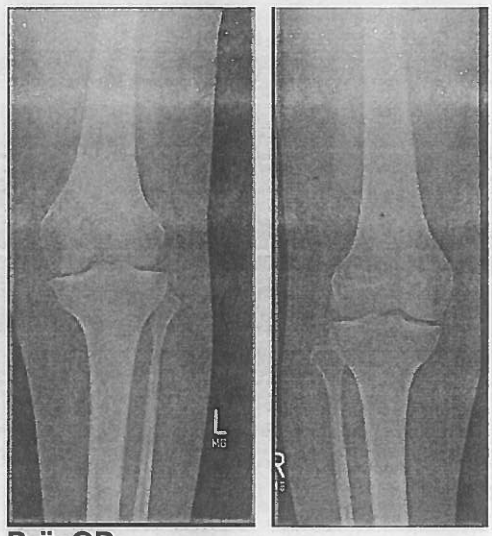

PräeOP

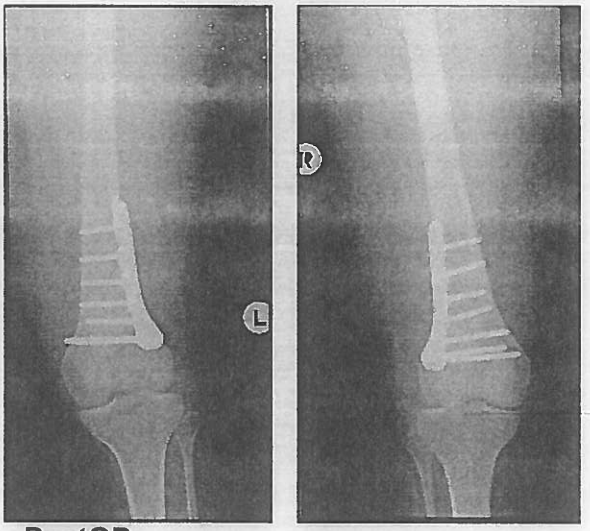

PostOP

Entlassungsbefund:
reizlose Wundverhältnisse, keine Thrombosezeichen, periphere DMS intakt, Transport in das Hotel mit KTW

Letzte Medikation:

Paracetamolsaft	bei Bedarf
Mono-Embolex 3000 s.c.	0-0-1 bis zum Erreichen der präoperativen Mobilität (Rezept ausgestellt)

Mit freundlichen kollegialen Grüßen

Dr. B. Leidinger
Chefarzt Kinder- u. Neuroorthopädie

EMBASSY OF THE
UNITED ARAB EMIRATES
MILITARY ATTACHE OFFICE
BERLIN

سفارة
الإمارات العربية المتحدة
مكتب الملحقية العسكرية
برلين

12.8.2015
649/14/s.s.

MEDICAL REPORT
Translation

Volmarstein
Orthopaedic Clinic
Paediatric Orthopaedics and Neuro-orthopaedics
Dr. Benedikt Leidinger

Patient: **Al Qassab, Meera,** * 22.8.1999

Outpatient: 12.8.2015

Diagnosis:
Hereditary spastic paraparesis
Condition after correction of neurogenic hip dysplasia
Severe crouching gait
Condition after supracondylar derotary femoral osteotomy bilateral in simultaneous operation

Procedure:
Continuation of rehabilitation in Holthausen for further 6 weeks.
Recommendation to perform Btx injection and treatment at medial hamstring muscle on the left and gastroc on the left

Prior to the operation Meera has been able to walk free but in marked crouching gait. Both knees had been flexed in crouching gait and turned inwards. Now weight-bearing and walking orthograde on the right side, on the left side buckling of the knee with manifest limp and reduced walking distance.
Today the pain on the left side has receded. On the right side no functional problem, on the left reduced active (-20°) and passive (-10°) knee extension. Functional pes equines on the left with upper ankle joint dorsal extension +20° with flexed knee and +/-0°° with extended knee.

Due to high functional impairment on the left side, we currently suggest treatment with Btx.

Extended rehabilitation treatment is acutely necessary. After Btx, follow-up treatment with rehabilitation therapy will be medically necessary for **6 weeks.** In this period patient's walking has to be improved before she is fit to travel.

Signed Dr. B. Leidinger (translated 13.8.2015)

TRANSLATION AUTHORIZED AND CONTROLLED BY THE
UAE EMBASSY - BERLIN
MILITARY ATTACHE - HEALTH OFFICE - BONN
ترجمة معتمدة من
سفارة الإمارات العربية المتحدة - برلين
الملحقية العسكرية - المكتب الصحي - بون
IN CASE OF DOUBT AS TO THE PROPER INTERPRETATION
OF THE REPORT THE GERMAN TEXT SHALL PREVAIL

جمهورية المانيا الاتحادية – برلين – شارع هيروشيما 18 – 20 الرمز البريدي 10785 تلفون : 0049 30 51651733 فاكس: 00493051651710
Germany – Berlin – Hiroshima Str. 18 – 20 Postal Code 10785 Tel. : 0049 30 51651733 – Fax. : 00 49 30 51651710/27

EMBASSY OF THE
UNITED ARAB EMIRATES
MILITARY ATTACHE OFFICE
BERLIN

سـفـارة
الإمارات العربية المتحدة
مكتب الملحقية العسكرية
برلين

2.9.2015
649/14/s.s.

MEDICAL REPORT
Translation

Johanniter Hospital Bonn
Department for Ophthalmology
PD Dr. Fries

Patient: **Al Qassab, Meera, *** 22.8.1999

Outpatient: 6.8.2015

Diagnosis:
Condition after strabismus operation, convergent strabismus, right eye: retinal hole, vitreous condensation with traction, left eye: condition after LACO retinal hole and degeneration and schisis, both eyes: condition after multiple laser retinopexy

Findings:
Visual acuity: R/ glasses 0.6 p L/ glasses 0.8 p
IOP: R/ 12 mmHg, L/ 12 mmHg
Anterior segment: R/L irritation-free
Fundus: R/L: circular retinal attachment, vitreous condensation, all foramina and degenerations sealed off.

Conclusion:
Meera has been diagnosed with retinal changes, multiple retinal holes and vitreous traction at the retina by myopia with risk of retinal detachment on both eyes. We performed laser coagulation on both eyes.
For further treatment, follow-up examination at our clinic will be absolutely necessary in 9-12 months.

Signed

TRANSLATION AUTHORIZED AND CONTROLLED BY THE
UAE EMBASSY - BERLIN
MILITARY ATTACHE - HEALTH OFFICE - BONN
ترجمة معتمدة من
سفارة الإمارات العربية المتحدة - برلين
الملحقية العسكرية - المكتب الصحي - بون
IN CASE OF DOUBT AS TO THE PROPER INTERPRETATION
OF THE REPORT THE GERMAN TEXT SHALL PREVAIL

(translated 9.9.2015)

EMBASSY OF THE
UNITED ARAB EMIRATES
MILITARY ATTACHE OFFICE
BERLIN

سـفـارة
الإمارات العربية المتحدة
مكتب الملحقية العسكرية
برلين

2.9.2015
649/14/s.s.

MEDICAL REPORT
Translation

Johanniter Hospital Bonn
Department for Ophthalmology
PD Dr. Fries

Patient: **Al Qassab, Meera, * 22.8.1999**

Outpatient: 6.8.2015

Diagnosis:
Condition after strabismus operation, convergent strabismus, right eye: retinal hole, vitreous condensation with traction, left eye: condition after LACO retinal hole and degeneration and schisis, both eyes: condition after multiple laser retinopexy

Findings:
Visual acuity: R/ glasses 0.6 p L/ glasses 0.8 p
IOP: R/ 12 mmHg, L/ 12 mmHg
Anterior segment: R/L irritation-free
Fundus: R/L: circular retinal attachment, vitreous condensation, all foramina and degenerations sealed off.

Conclusion:
Meera has been diagnosed with retinal changes, multiple retinal holes and vitreous traction at the retina by myopia with risk of retinal detachment on both eyes. We performed laser coagulation on both eyes.
For further treatment, follow-up examination at our clinic will be absolutely necessary in 9-12 months.

Signed

TRANSLATION AUTHORIZED AND CONTROLLED BY THE
UAE EMBASSY - BERLIN
MILITARY ATTACHE - HEALTH OFFICE - BONN
ترجمة معتمدة من
سفارة الإمارات العربية المتحدة - برلين
الملحقية العسكرية - المكتب الصحي - بون
IN CASE OF DOUBT AS TO THE PROPER INTERPRETATION
OF THE REPORT THE GERMAN TEXT SHALL PREVAIL

(translated 9.9.2015)

EMBASSY OF THE
UNITED ARAB EMIRATES
MILITARY ATTACHE OFFICE
BERLIN

سـفـارة
الإمارات العربية المتحدة
مكتب الملحقية العسكرية
برلين

15.01.2015
649/14/g.a.

MEDICAL REPORT
(Translation)

JOHANNITER HOSPITAL BONN
Department of Ophthalmology
Dr. U. Fries

Meera Ali Mohammed Abdulrahman Al Qassab, dob 22.08.1999
Treatment on 14.01.2015 (OPD)

Diagnosis:
C.a. squint operation, strabismus convergens, RE: foramina retinae, vitreous body densification with traction; LE: foramina retinae, degeneration and schisis

Procedures:
Other operations for fixation of the retina. Laser retinopexy on 14.01.15

Findings:

Vision	RE / own glasses 0.5-8.0 -3.0 A175° = 0.6 LE/ own glasses 0.6, other glasses don't improve	
IOP	RE 13.4 mm Hg	LE 11.7 mm Hg
Anterior chamber	irritation-free	
Fundus:	RE: optic disk very small, tilted disk, degeneration and foramina retinae, retinal traction under vitreous body membrane, at 6 h round hole with vitreous body densification 7-5 h with traction LE: in the lower region at 5 h foramen and degeneration, membrane in the vitreous body up to 9 h, at 6 h degeneration and schisis, in the upper region degeneration at 3 h	

Orthoptic status:
Cover test: strabismus convergens right side / alternans; prism cover test: far distance +4° + VD 6°, near distance+ 5° + VD 5°, slightly fluctuating less sometimes, excessive recovery movements diss. Part at VD, motility: when looking to the right side + VD 5, when looking to the left side + VD 8, no obvious V-symptom, squint operation not required.
The squint findings are not the cause for the motor unsteadiness.

Pentacam:
RE corneal thickness 547 µm, thinnest region 542 µg, depth anterior chamber 2.84 mm, volume anterior chamber 140 mm³
LE corneal thickness 517 µm, thinnest region 496 µg, depth anterior chamber 2.67 mm, volume anterior chamber 128 mm³

Meera Ali Mohammed Abdulrahman Al Qassab, dob 22.08.1999

Summary:

Meera suffers from changes of the retina, several foramina retinae and vitreous body traction at the retina through myopia with the threat of retinal detachment at both eyes. We performed a laser coagulation at the right eye. We are planning to perform a laser coagulation also at the left eye; in case the therapy is not sufficient a cryo-coagulation might have to be carried through under general anesthesia on in-patient conditions. An appointment for the laser coagulation at the left eye has already been fixed for the 21.01.15.

Signature

Translated: 15.01.2015

TRANSLATION AUTHORIZED AND CONTROLLED BY THE
UAE EMBASSY - BERLIN
MILITARY ATTACHE - HEALTH OFFICE - BONN
ترجمة معتمدة من
سفارة الإمارات العربية المتحدة - برلين
الملحقية العسكرية - المكتب الصحي - بون
IN CASE OF DOUBT AS TO THE PROPER INTERPRETATION
OF THE REPORT THE GERMAN TEXT SHALL PREVAIL

UNITED ARAB EMIRATES
MINISTRY OF COMMUNITY DEVELOPMENT

الإمارات العربية المتحدة
وزارة تنمية المجتمع



Disabled ID Card بطاقة معاق

Card ID :	2012-0000027	الرقم :
Date of Issue :	2017-01-17	تاريخ الإصدار :
Date of Expiry :	2022-01-16	تاريخ الإنتهاء :
	الامارات العربية المتحدة	الجنسية
Nationality :	UNITED ARAB EMIRATES	
Date of Birth :	1999-08-22	تاريخ الميلاد :
	ميره علي محمد القصاب	الاسم :
Name :	Meera Ali Mohammed Al Qassab	
Disability Type :	Physical disability	نوع الإعاقة : جسدية

أنتم شركاؤنا في التنمية
You are our partners in the development

تعتبر هذه البطاقة مستنداً رسمياً تكفل لحاملها الحقوق الواردة في القانون الإتحادي رقم (29) لسنة 2006.

This Card is an official document guarantee to the holder the rights listed in the Federal Law No. 29 of the year 2006.

	Support Equipments	أجهزة الدعم
	Cochlear implant	زراعة قوقعة
	Crutch	عكاز
	Hearing Aid	جهاز سمع
	Prosthesis	طرف صناعي
*	Wheelchair	كرسي متحرك
	White cane	عصا بيضاء
	Accompanied with a person	مع مرافق

FCI400495

يرجى من يعثر على هذه البطاقة الاتصال على هاتف رقم 2430932 9 971+ أو 6011154 4 971+
In case of finding this card please call +971 9 2430932 or +971 4 6011154


هيئة تنمية المجتمع
Community Development Authority
"سند" لذوي الإعاقة
"Sanad" for People with Disability
Name
الإسم
ميره علي القصاب
Meera Ali Al Qassab
Card No.
رقم البطاقة
1000243
Type of disability
نوع الإعاقة
حركية
Physical
A
A CITY FOR EVERYONE
مدينة للجميع


هيئة تنمية المجتمع
Community Development Authority
www.cda.gov.ae
800 2121
/CDAdubai1
@CDA_dubai
@CDA_dubai
CDAdubaigov
Expiry Date: تاريخ الإنتهاء
20/07/2021
سند
sanad

United Arab Emirates

دولة الإمارات العربية المتحدة

Identity Card

بطاقة هوية

ID Number / رقم الهوية
784-1999-0694271-1





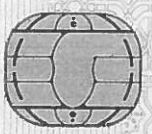

الإسم: ميره علي محمد عبدالرحمن القصاب

Name: Meera Ali Mohamed Abdulrahman Alqassab

الجنسية: الإمارات العربية المتحدة

Nationality: United Arab Emirates

Sex: F الجنس: أنثى

Date of Birth 22/08/1999 تاريخ الولادة

Signature / التوقيع

Expiry Date / تاريخ الإنتهاء
15/12/2026

Card Number / رقم البطاقة
081248079

2540398/01

عند العثور على هذه البطاقة الرجاء إرجاعها إلى جهة إصدارها أو إلى أقرب مركز شرطة

If you find this card, please returnit to the issuing organization or to the nearest police station.

06000098B7641374

IDARE08124807999784199906942711
9908224F2612155ARE<<<<<<<<<<<1
ALQASSAB<<MEERA<ALI<MOHAMED<AB

UNITED ARAB EMIRATES
VISAS

الإمارات العربية المتحدة
التأشيرات

UNITED ARAB EMIRATES

الإمارات العربية المتحدة

Type P
Country Code ARE
Passport No HFK169356
رقم الجواز

Names
MEERA ALI MOHAMED ABDULRAHMAN ALQASSAB
الإسم
ميرة علي محمد عبدالرحمن القصاب

Nationality
United Arab Emirates
الجنسية
الإمارات العربية المتحدة

Date of Birth
22/08/1999
تاريخ الميلاد

Sex
F
الجنس
أنثى

Place of Birth
DUBAI
مكان الميلاد
دبي

Date of Expiry
25/08/2019
تاريخ الانتهاء

Date of Issue
26/08/2014
تاريخ الاصدار

Issuing Authority
DUBAI
جهة الاصدار
دبي

Holder's Signature
No signature
توقيع حامل الجواز
بدون التوقيع

P<AREALQASSAB<<MEERA<ALI<MOHAMED<ABDULRAHMAN
HFK1693560ARE9908224F1908251<<<<<<<<<<<<<<0

UNITED ARAB EMIRATES
VISAS

الإمارات العربية المتحدة
التأشيرات

الرقم الموحد 2084933

رقم الاضبارة 120770

UNITED ARAB EMIRATES
VISAS

الإمارات العربية المتحدة
التأشيرات